


Chapter 6



Abdominal, Inguinal and Perineal Region

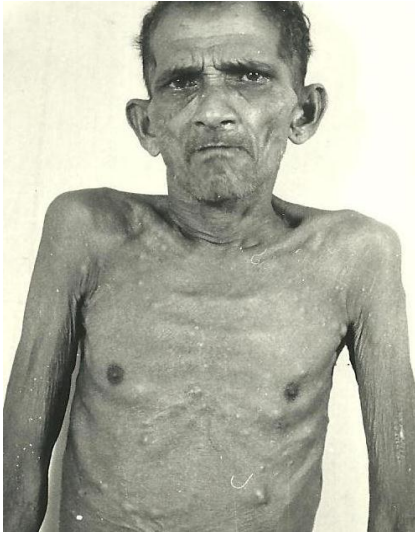
6.1 Abdominal Swellings; Advanced Cancers

Multiple cutaneous metastases; probably from pancreatic cancer (6.1a).

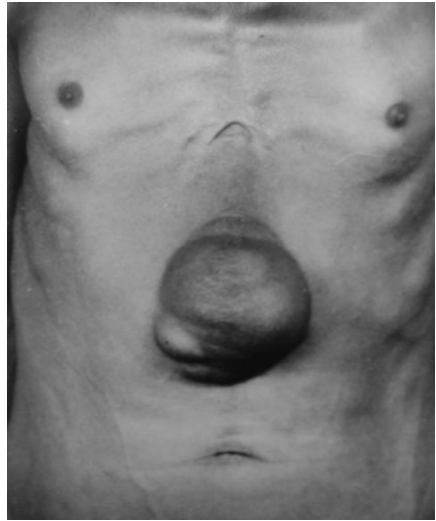
Epigastric neoplastic mass from gastric or pancreatic cancer (6.1b).

Malignant ascites with umbilical metastases [Sister Joseph nodule (6.1c).

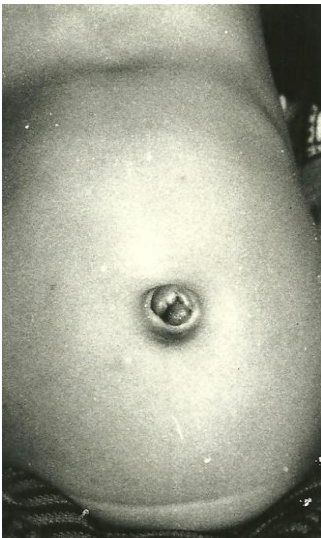Paraumbilical hernia is more common in adults. Umbilical hernia is rare (6.1d).
An underlying abdominal pathology must be excluded in such cases.



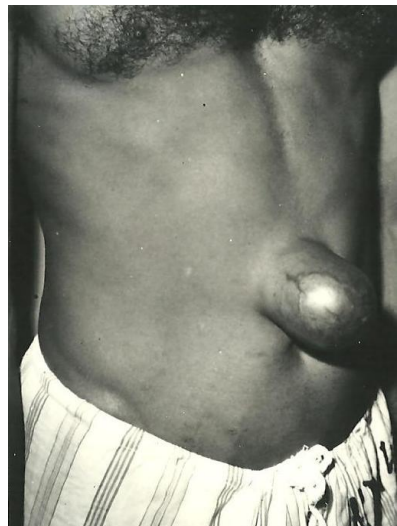6.1a



6.1b



6.1c



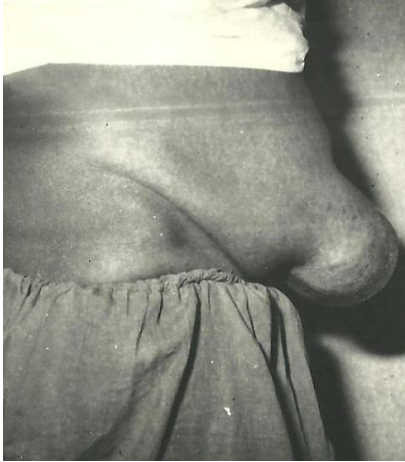6.1d

6.2 Abdominal Swelling

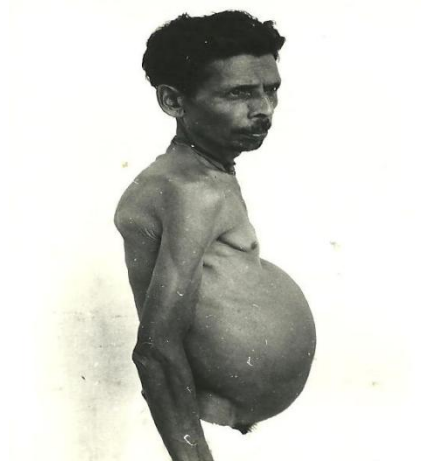Large ventral hernia (6.2a).

Massive ascites with cachexia, most likely malignant (6.2b).

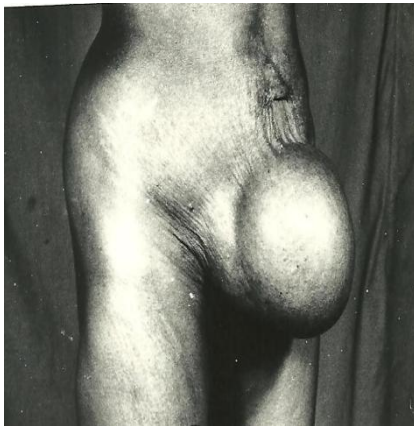
Incisional hernia can become massive when ignored [6.2c, 6.2d].



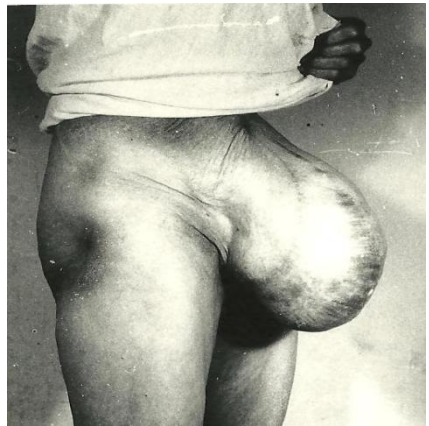6.2a



6.2b



6.2c

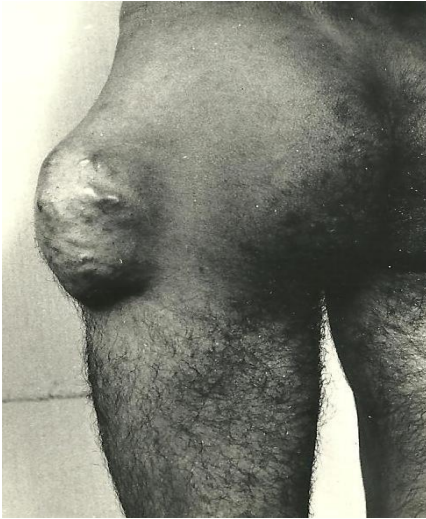

6.2d

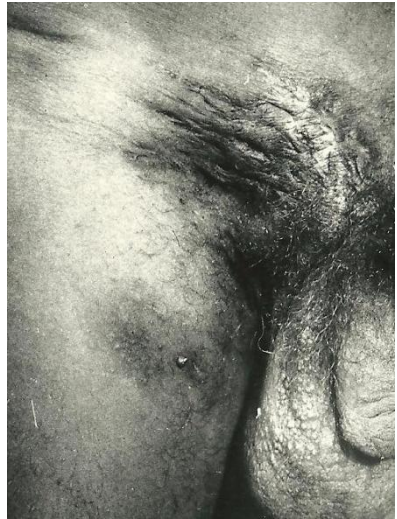
6.3 Misc. Swellings

Cystic lesion at the greater trochanter can be a bursa or cold abscess (6.3a).

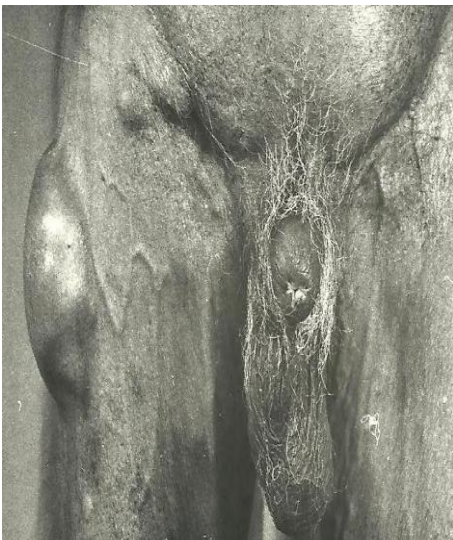
Lymphomamay involve inguinal glands (6.3b, 6.3c, 6.3d.). However, they are more likely to be lymphatic metastases from primary cancers in the lower limbs or perineum.



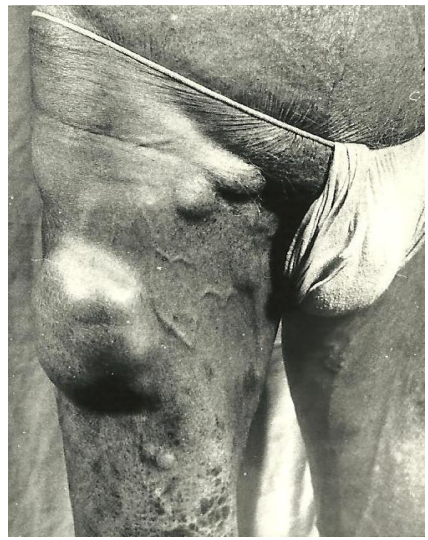6.3a



6.3b



6.3c



6.3d

6.4 Inguino-Scrotal Swellings

Inguinal swellings.

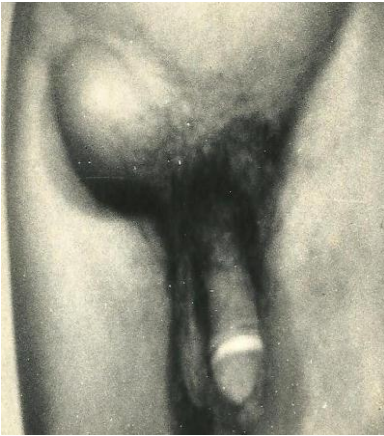Differential diagnosis.

6.4a. Cold abscess.

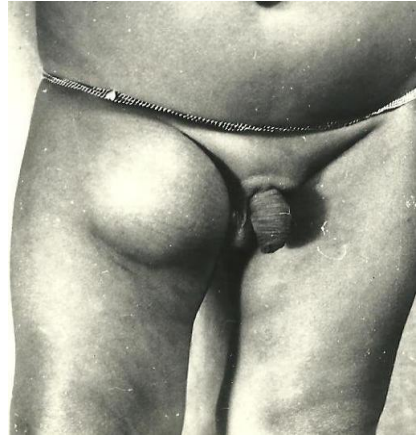6.4b. Embryonal tumor of 'Ectopic testis' [very rare]. Note empty scrotum.

6.4c. Cystic lesion can be a cold abscess from spinal tuberculosis [Pott's spine].

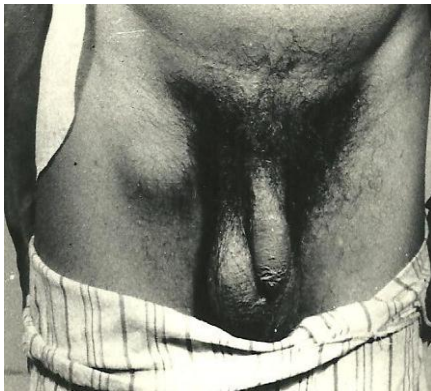6.4d. Inguinal hernia.



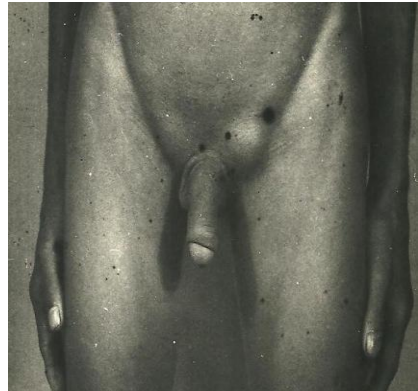6.4a



6.4b



6.4c



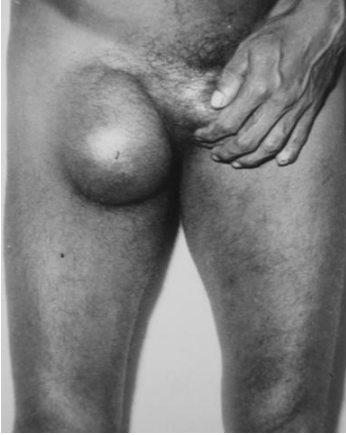6.4d

6.5 Inguino-Scrotal Swellings [Contd.]

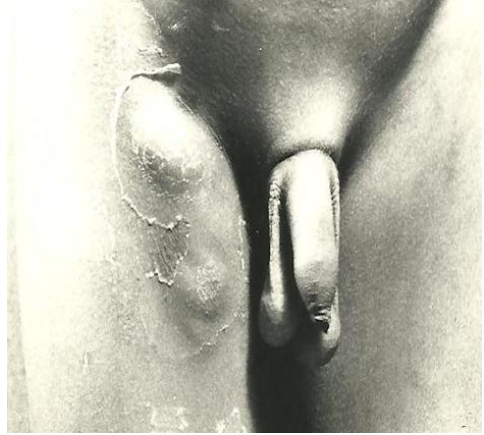6.5a. Lymphocele.

6.5b. Inguinal lesion caused by 'Guinea worm' [Dracunculusmelitinensis].

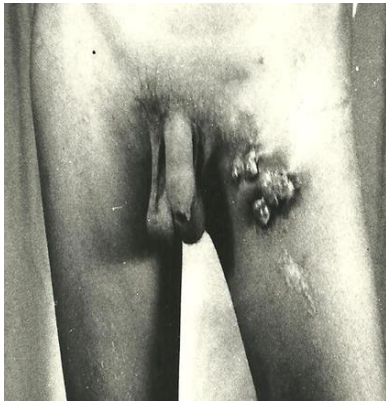6.5c & 6.5d, Cutaneous Fungal lesions [Actinomycosis].



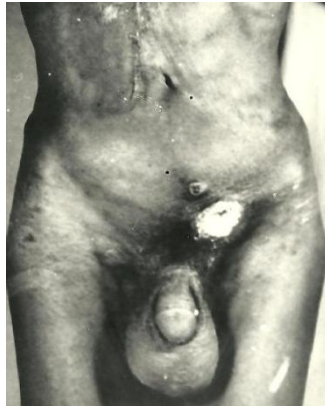6.5a



6.5b



6.5c



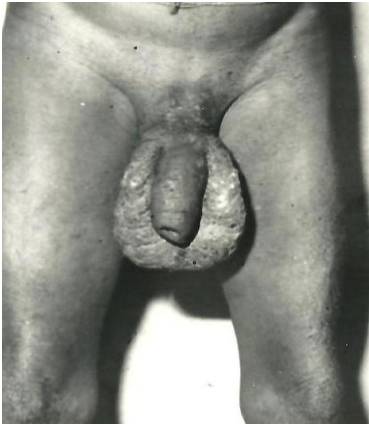6.5d

6.6 Inguino-Scrotal Swellings [Contd.]

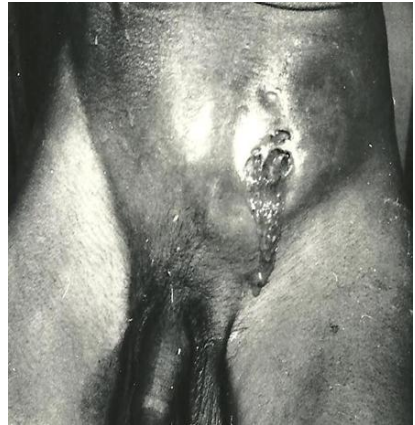6.6a. Filarial scrotum.

6.6b. Fecal fistula.

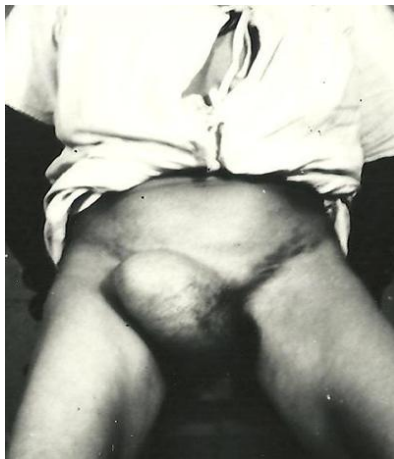6.6c. Inguinal hernia in a female.



6.6a



6.6b

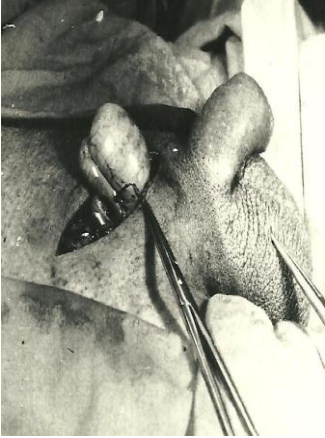


6.6c

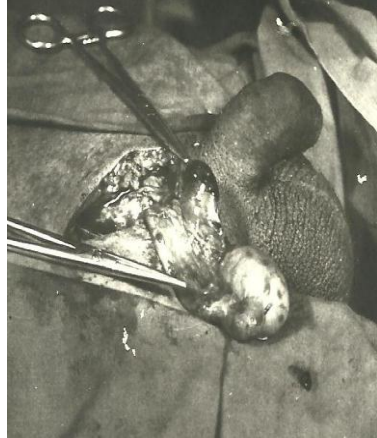6.7 Undescended Testis

6.7a, 6.7b. Undescended testis.

Operative findings: forceps point at empty scrotum (6.7a).



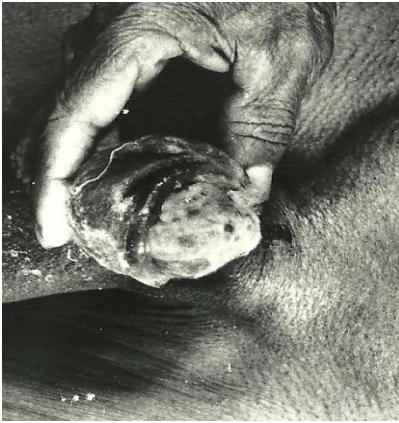6.7a



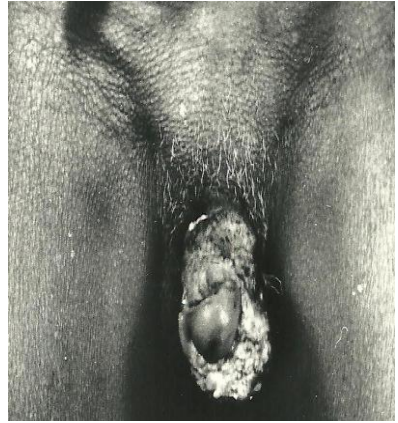6.7b

6.8 Penile Cancers

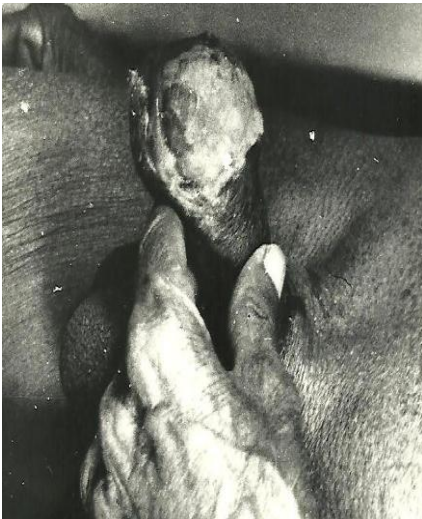Penile cancers are the result of poor hygienic conditions. In uncircumcised persons, smegma, irritating smelling secretion, collects in sulcus and starts neoplastic change (6.8a, 6.8b, 6.8c, 6.8d).



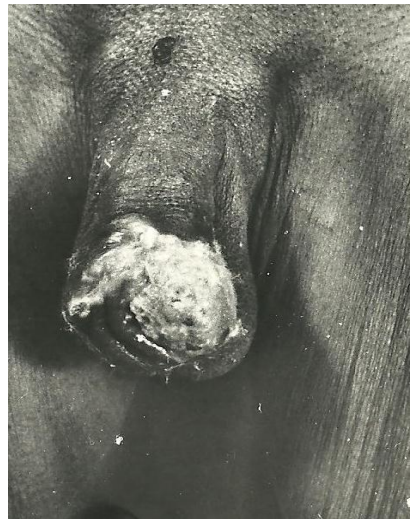
6.8a



6.8b



6.8c



6.8d

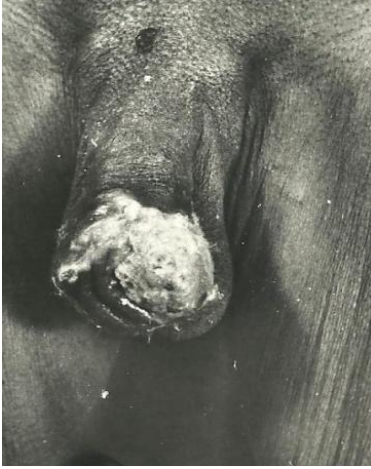6.9 Penile Lesions

6.9a. Carcinoma penis.

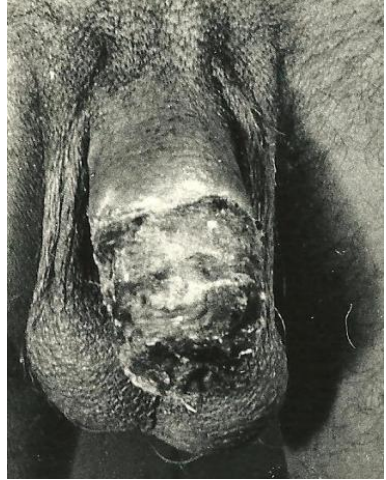6.9b. Necrosis of penile skin.

6.9c. Glove avulsion of penile and scrotal skin.

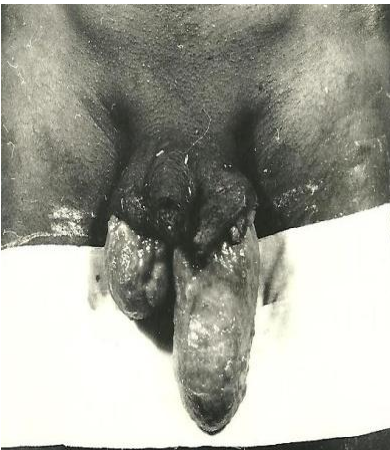6.9d. 'Phagedena' is infective symbiotic gangrene of scrotum and penis.



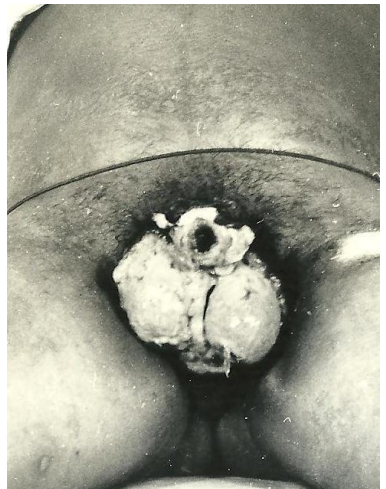
6.9a



6.9b



6.9c

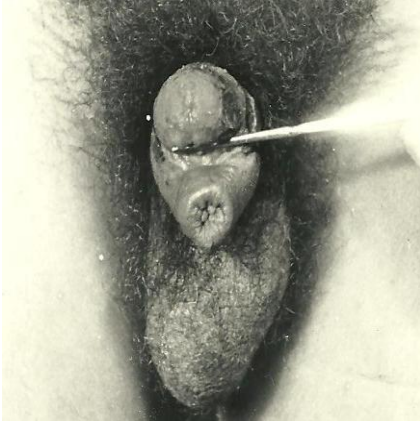

6.9d

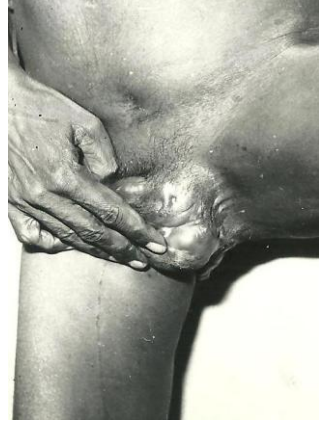6.10 Genital Lesions

6.10a, 6.10b. Urinary fistula at bulbous part of penile urethra can be Hypospadias in an adult or fistula secondary to gonococcal urethral stricture.

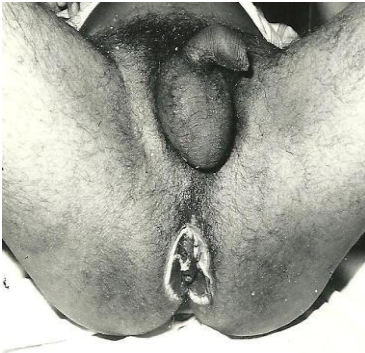6.10c, 6.10d. Perineal and vulval ulcerative necrosis following local herbal applications.



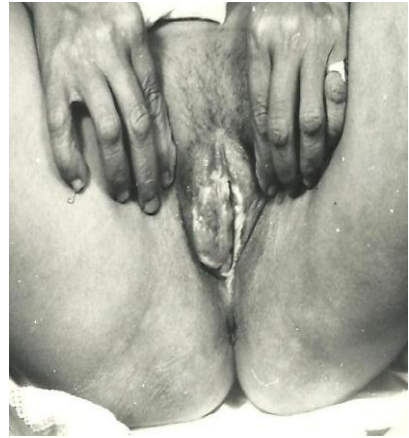6.10a



6.10b



6.10c

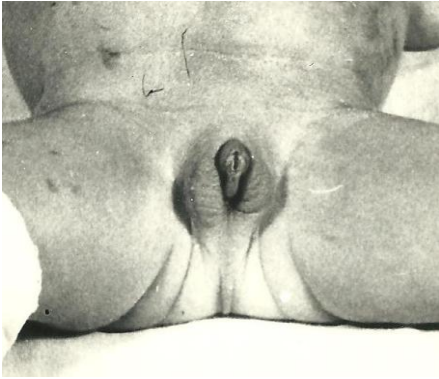

6.10d

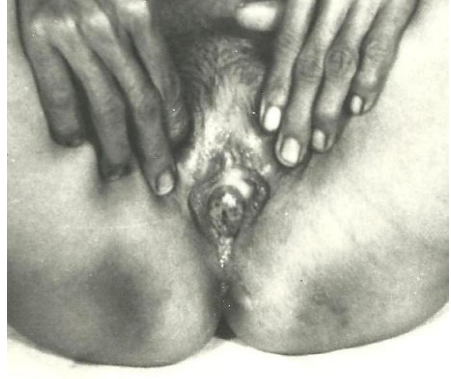6.11 Genital Lesions [Contd.]

6.11a, 6.11b. Hermaphrodites.

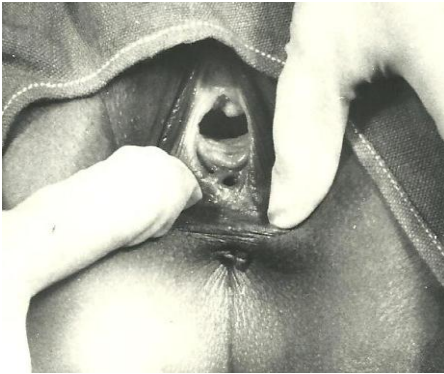
6.11c, 6.11d. Recto-vaginal fistula.



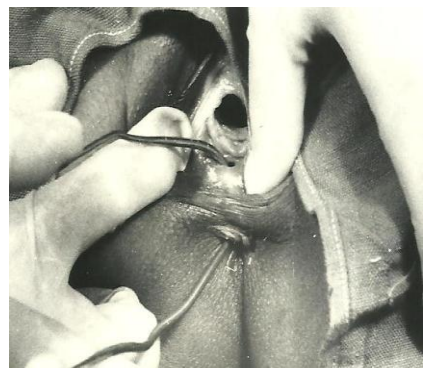
6.11a



6.11b



6.11c



6.11d

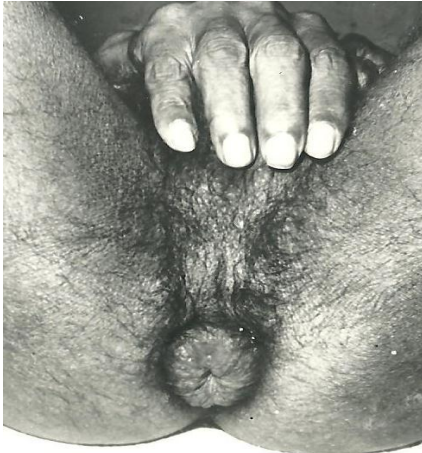6.12 Anal Lesions

6.12a. Partial rectal prolapsed.

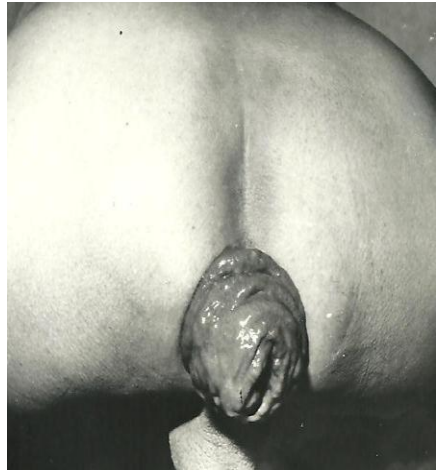6.12b. Complete rectal prolapsed.

6.12c. Anal stenosis following multiple surgical manipulations.

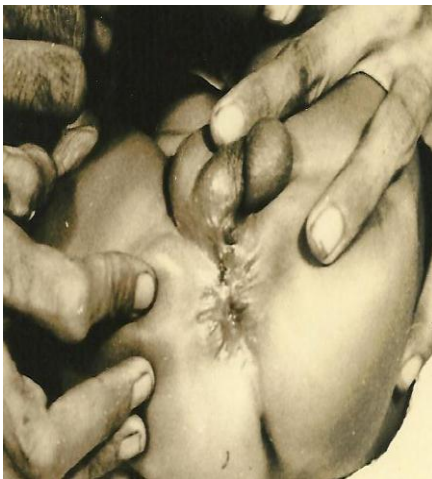6.12d. Perianal warts, viral or venereal.



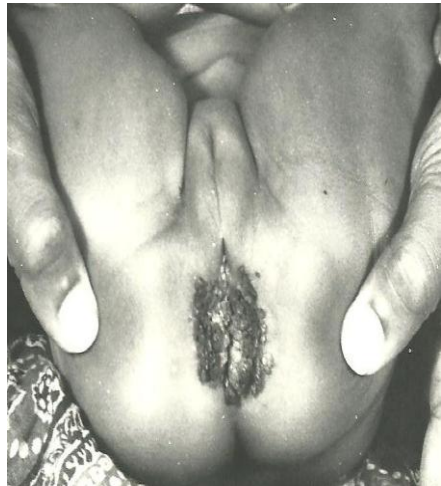6.12a



6.12b



6.12c



6.12d

6.13 Misc. Lesions

An Abdomino-Thoracic Case

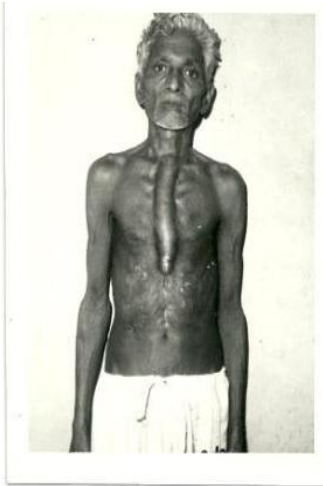
This is a case of advanced carcinoma of the esophagus. He had severe dysphagia, requiring urgent action.

Being tumor, it was not dilatable. No stents were available. A bypass was the only option. Subcutaneous Pre-Sternal Colon Bypass was preferred. It required minimal manipulation in a poor risk patient. Cosmetically it does not look good, but functionally it relieved the symptoms. Moreover, patients himself could manipulate the bolus down by massaging over the subcutaneous colon. My patient and I, both were satisfied.

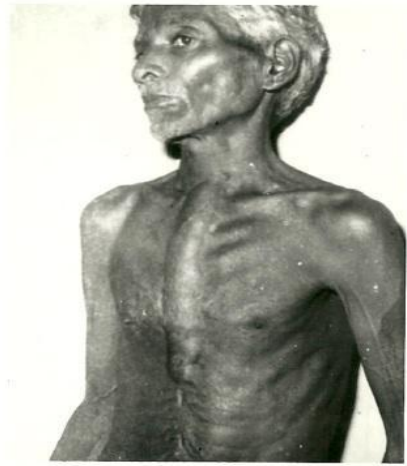6.13 [a] and [b] are the postoperative pictures of this patient.

6.13 [c] is the picture of an Ileal Conduit with Ileostomy as newly fashioned bladder after total cystectomy for urinary bladder carcinoma.

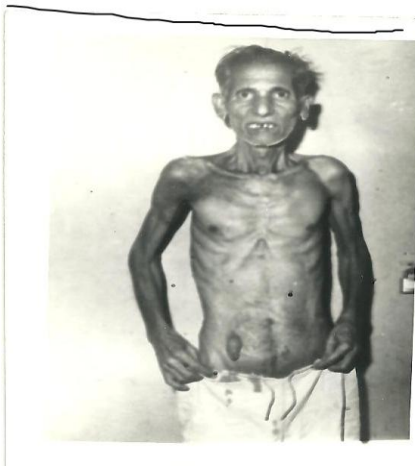
6.13 [d] shows an isolated plexiform neurofibroma of buttock, a rare site.



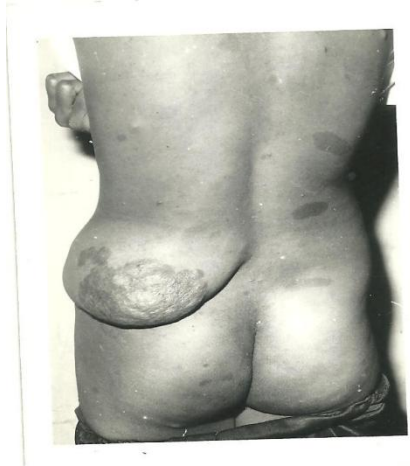6.13 a



6.13 b



6.13 c



6.13 d

